

**Pets Have  
Teeth Too!**



# Dental Report Card

Pets often go for months and even years with painful gingivitis, fractured teeth or severe tooth root abscesses without noticeable clinical signs to the owner. **Proper dental care can potentially add years of life and happiness to your pet.**

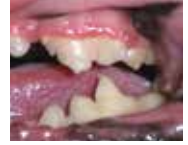Date: \_\_\_\_\_ Patient \_\_\_\_\_



## NICE JOB!

No sign of plaque or tartar. Brushing your pet's teeth regularly is ideal.

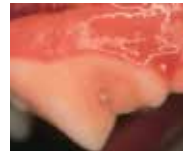
Home dental care is needed to maintain these healthy teeth and gums. There are products available to help make home dental care easier and hassle free.



## STAGE 1 – (reversible stage) Mild gingivitis:

The margin of attached gum is inflamed and swollen. Plaque can be seen on the teeth.

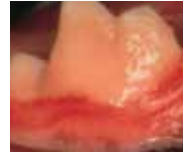
Home dental care is needed. If there is no improvement, dental cleaning is needed to remove current plaque buildup.



## STAGE 2 – (reversible stage) Moderate gingivitis:

The entire gum is inflamed and swollen. The mouth is painful and odor is noticeable. Infection may start to destroy gum and bone tissue.

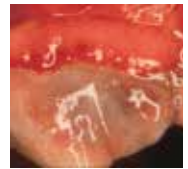
Dental cleaning to remove calculus is needed **within the next month**. A calculus control diet and home dental care are needed afterward for prevention.



## STAGE 3 – (potentially reversible stage) Severe gingivitis:

The gums are chewed away and they are damaged by infection and calculus. A sore mouth, loose teeth and bad breath are common.

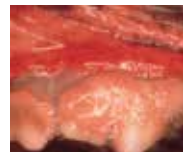Dental cleaning to remove calculus is needed **immediately**. A calculus control diet and home dental care are needed afterward for prevention.



## STAGE 4 – (irreversible stage) Periodontal disease:

Chronic infection is destroying the gums, teeth and bone. Bacteria are spreading through the body via the bloodstream and may damage the kidneys, liver and heart.

Dental cleaning to remove calculus is needed **immediately**. The teeth may be loose and need extraction. A calculus control diet and home dental care are needed afterward for future prevention.



Dental photos courtesy of:  
Dr. Jan Bellows



**Feline Resorptive Lesion:** There is a cavity-like lesion in at least one tooth. This "hole" will get larger and larger until the tooth breaks, causing more and more pain. This disease process cannot be medically stopped. **Extraction of the tooth needs to be scheduled to stop your cat's pain.**

**ORDER FROM**  
phil winter's  
marketing communications  
[www.VetPracticeMarketing.com](http://www.VetPracticeMarketing.com)  
800 - 803-8832  
[phil@philwinter.com](mailto:phil@philwinter.com)